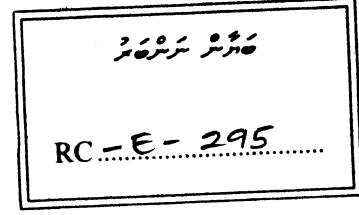


**Presidential Commission**  
**The President's Office**  
**Male'**  
**Republic of Maldives**



Name: Dr. Madhab Lamichhane (Dr. Madhab)  
Address: IGMH Quarters  
Room no: 108  
Male'  
Age: 27 yrs (16<sup>th</sup> June 1976)  
Gender: Male  
Nationality: Nepalese  
Passport No: 1581229  
Occupation: Medical Officer / IGMH  
Date: 23<sup>rd</sup> September 2003

*Madhab Lamichhane*

I have been working in Indira Gandhi Memorial Hospital (IGMH) for 9 months. I was on night duty (8:00 pm – 8:00 am) in the emergency department on 19<sup>th</sup> September 2003. While I was on duty, I got a call from Dr. Razeer (Dr. Ahmed Razeer) at 5:45 am and he told me that a custodial death is on the way and to inform surgeon on call and physician on call. The dead body was accompanied to IGMH by two persons from Department of Corrections and some National Security Service (N.S.S) staff. I know one of the Department of Correction staff Mr. Adam (Adam Ismail). I asked him to give some history but for official reasons he refused to give history. The dead body was directed to the dressing room, where usually the dead bodies are examined. By that time Physician on call Dr. Quraishi (Dr. SMS Quraishi) and surgical medical officer on duty Dr. Shifan (Dr. Mohamed Shifan) and Dr. Farzana (Dr. Farzana Firdous), have arrived and they proceeded to examine the

*Madhab Lamichhane*

*Madhab Lamichhane*

dead body. I did not examine the dead body completely but I noticed some of the external injuries. His T-shirt was wet and torn and body was covered with sand. There were abrasions on his forehead, and the nasal tip. Multiple bruise marks were seen on both upper arm, forearm and wrist. I also noticed bruises on the abdomen, both thigh and legs. Rigor mortis was obvious till foot end. Post-mortem lividity was seen on his back. The doctors attending the dead body recorded all the injuries and he was subjected to X- rays and CT scanning to establish the cause of death. In the meantime I wrote the death certificate of Ivan (Hassan Ivan Naseem, M. Asia) in which I wrote the cause of death as multiple injuries as the reports were not available at that time. Chest X-ray was the first report available and it owed a right pneumothorax due to collapsed lung with mediastinal emphysema and a fracture of right seventh rib. CT lung later reported as having a hemorrhagic contusion in lower zone of left lung with right hydro-pneumothorax with collapsed right lung. There was a hematoma in left temporo-parietal region and air fluid levels in trachea, eosophagus and the stomach. In my opinion Ivan had died due to the injuries he had sustained. It is not likely to be self inflicted injuries. The most likely injury that must have caused his death is the injury to the lung leading to insufficient oxygen delivery to the tissues. Though a post-mortem examination will be an extra proof for documentation, the post-mortem CT-evaluation by itself had given enough information to suggest a cause of death. This is a true statement given by me voluntarily to the Presidential Commission establish to investigate the death of Hassan Ivan Naseem, M. Asia at Maafushi jail on 19<sup>th</sup> September 2003.

*Madhab Lamichhane*

Dr. Madhab Lamichhane



Statement taken by: Dr. Mohamed Solih

*Mohamed Solih*

Witness: Dr. Ibrahim Yasir Ahmed

*Ibrahim Yasir Ahmed*

Ms. Aishath Mohamed Didi

*Aishath Mohamed Didi*